Imaging of Lisfranc Injury and Midfoot Sprain

Stephen F. Hatem, MD

KEYWORDS

• Lisfranc injury • Midfoot sprain • MRI

"Lisfranc" is one of the best known orthopedic eponyms. Unfortunately, the term is imprecise. Lisfranc is applied to a multitude of normal structures and various injuries: the Lisfranc joint, Lisfranc ligament, Lisfranc injury, and Lisfranc fracture-subluxation or dislocation. Jacques Lisfranc, a field surgeon in Napolean's army, described none of these; rather, he described a forefoot amputation technique that could be performed in less than 1 minute.[1] The site of that amputation, the tarsometatarsal joint, is now known as the Lisfranc joint, and is the common denominator among the various eponyms. The strong interosseous ligament between the first cuneiform (C1) and second metatarsal (M2), is known as the Lisfranc ligament, and is vital to the support of the tarsometatarsal joint. Injuries to the tarsometatarsal joint can be caused by low or high impact. The low-impact midfoot sprain is called a Lisfranc injury; the high-impact injuries are called Lisfranc fracture-subluxation or Lisfranc fracture-dislocation. Only recently has the orthopedic and radiology literature emphasized this distinction and investigated the imaging and clinical differences, highlighting the often-subtle midfoot sprain.

These distinctions are important for more than accurate and precise communication. Lisfranc fracture dislocations are uncommon, with an estimated incidence of 1 per 55,000, and account for only 0.2% of all fractures.[1] Yet midfoot sprains are common in athletes and occur in up to 4% of American football linemen per season.[2]

Up to 35% of Lisfranc injuries are initially misdiagnosed or overlooked.[3] Delays in diagnosis may be related to multiple factors, including a low index of suspicion,[4,5] distracting injuries in patients who have polytrauma,[4] or the subtlety or masking of radiographic findings.[5] Numerous authors have emphasized the importance of prompt diagnosis in minimizing the risk for long-term complications, such as residual ligamentous instability or posttraumatic degenerative arthritis.[1,6–8] Perhaps not surprisingly, Calder and colleagues[4] have shown that poor patient outcomes are associated with a delay in diagnosis of more than 6 months and presence of a compensation claim. Lisfranc injuries are reportedly the second most common injury in malpractice litigation against radiologists and emergency physicians.[9]

Injuries to the tarsometatarsal joint and of the Lisfranc ligament present a challenge.[1] They are difficult to diagnose and[2] outcomes worsen as diagnosis is delayed.[10] As a result, radiologists and clinicians must have a clear understanding of the relevant nomenclature, anatomy, injury mechanisms, and imaging findings.

ANATOMY

The Lisfranc joint, or tarsometatarsal joint, defines the junction of the midfoot and forefoot, consisting of the following articulations between nine bones (**Fig. 1**):

- The medial, or first cuneiform (C1), with the hallux, or first metatarsal (M1)
- The middle, or second cuneiform (C2), with the second metatarsal (M2)
- The lateral, or third cuneiform (C3), with the third metatarsal (M3)
- The cuboid (Cu), with the fourth (M4) and fifth metatarsals (M5)

Department of Musculoskeletal and Emergency Radiology, Cleveland Clinic, Cleveland Clinic Main Campus, Mail Code A21, 9500 Euclid Avenue, Cleveland, OH 44195, USA
E-mail address: hatems@ccf.org

Radiol Clin N Am 46 (2008) 1045–1060
doi:10.1016/j.rcl.2008.09.003
0033-8389/08/$ – see front matter

radiologic.theclinics.com

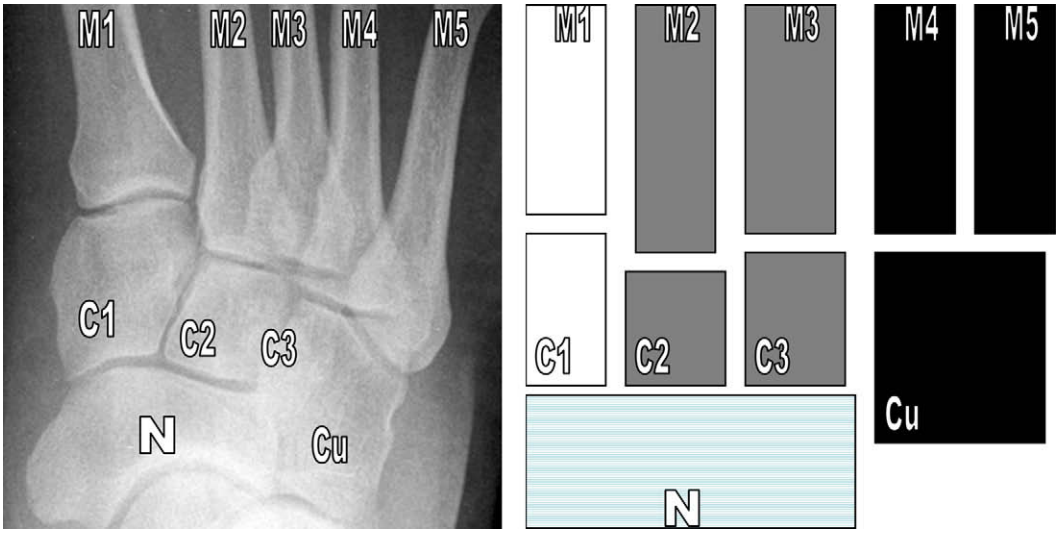

Fig. 1. Normal AP radiograph and schematic of the osseous relationships of the Lisfranc joint. Note how M2 is recessed in a mortise formed by C1 and C3. White shading indicates the medial column, gray the middle column, and black the lateral column. C1, first (medial) cuneiform; C2, second (middle) cuneiform; C3, third (lateral) cuneiform; Cu, cuboid; M1, first metatarsal; M2, second metatarsal; M3, third metatarsal; M4, fourth metatarsal; M5, fifth metatarsal; N, navicular.

These articulations occur within three separate synovial compartments. The first tarsometatarsal joint forms the medial compartment. The second and third tarsometatarsal joints share a capsule that communicates with the first and second intercuneiform and naviculocuneiform joints to form the central compartment. The articulations of the cuboid with the fourth and fifth metatarsals share a capsule, creating the lateral compartment.[11] These joints contribute to the columnar description of the foot: the medial column is defined as the first ray, including the medial cuneiform; the middle column includes the second and third rays and cuneiforms; and the lateral column includes the fourth and fifth rays with the cuboid.[12]

Additional osseous relationships are also important in the assessment of imaging and injury of the Lisfranc joint. These include the intercuneiform joints, especially C1-C2, the naviculocuneiform joint (N-C1C2), and those between the bases of the metatarsals.

These osseous relationships contribute to the intrinsic stability of the tarsometatarsal joint, with M2 the key structure.[13] It has been reported that up to 90% of patients who have Lisfranc injuries have a fracture, typically of the plantar aspects of the medial base of M2 or distal lateral aspect of C2.[3,14] In the coronal (short axis) plane, the osseous structures form a so-called "Roman arch." M2 represents the "keystone" because of its dorsal-most position and trapezoidal articular surface, broad base dorsally, and apex at its plantar surface. This transverse arch is an inherently stable configuration mechanically[13] but predisposes to dorsal displacement (**Fig. 2**).[15]

When viewed in the axial (long axis) plane, as on an anteroposterior (AP) radiograph, the tarsometatarsal joint is S-shaped.[16] The second metatarsal is recessed proximally with respect to the bases of the hallux and third metatarsals with a resultant mortise configuration. Peicha and colleagues[16] evaluated this configuration in 33 patients who suffered Lisfranc injuries, mostly low-impact sports-related injuries. The depth of the mortise was measured on routine foot radiographs in injured patients. The medial depth was measured on the AP view and the lateral depth on the oblique projection. Comparison was to a control group of measurements from cadavers without Lisfranc injuries. The mortise depth was significantly shallower medially in injured patients (8.95 mm versus 11.61 mm) than in controls ($P<.00001$). They theorized that a longer medial mortise depth allows for a broader and presumably stronger Lisfranc ligament at C1-M2, which protects against injury.

The ligamentous anatomy is complex and variable in course, number, and insertions (**Fig. 3**). [11] This complexity is reflected in the literature, both orthopedic and radiologic, which is inconsistent with respect to nomenclature and description.[17] A simplified description of the ligamentous constraints (see **Fig. 3**A) is commonly described,

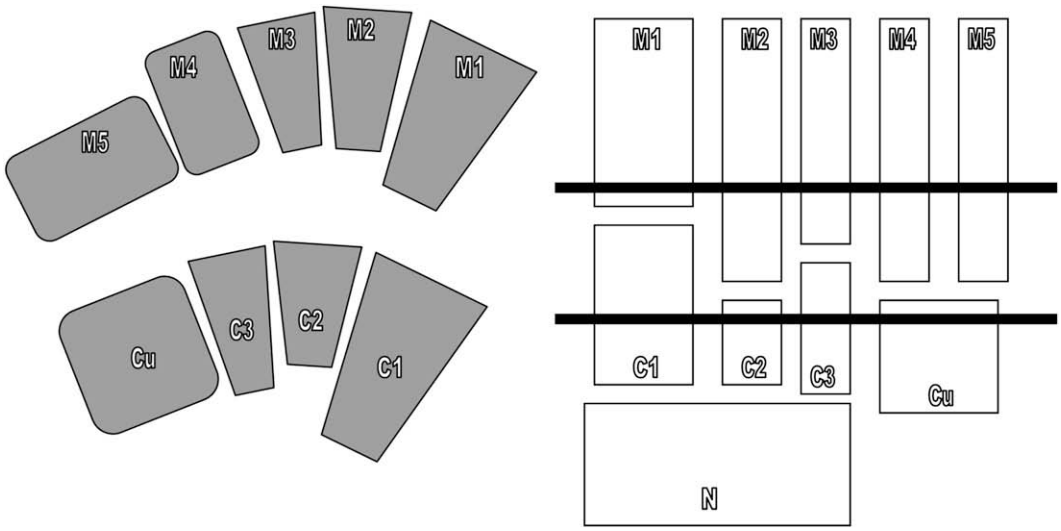

Fig. 2. Asymmetric Roman arch of the tarsometatarsal region in the short axis. Note the keystone position of the second metatarsal (M2) and cuneiform (C2). Also note how an image slice between these variably includes both cuneiforms and metatarsal bases. On cross-sectional imaging, cross referencing using a longitudinal plane allows confident localization.

which emphasizes the presence of tarsometatarsal ligaments at each articulation (C1-M1, C2-M2, C3-M3, Cu4-M4, Cu-M5) and three intermetatarsal ligaments (M2-M3, M3-M4, M4-M5). In general, these are described as having weaker dorsal and stronger plantar components. Most importantly, a point of weakness occurs between M1 and M2 where there is no intermetatarsal ligament. Rather, an additional tarsometatarsal ligament that courses obliquely from C1-M2 (the Lisfranc ligament)[18] plays the crucial role of supporting the base of C2 in its mortise between C1 and C3 and in its dorsal, keystone position in the transverse arch.

The detailed anatomic study by De Palma and colleagues in 1997[11] further elucidated the ligamentous relationships of the Lisfranc joint and has served as the anatomic model for subsequent biomechanical studies.[19,20] De Palma and colleagues emphasized a ligamentous system based on location (dorsal, interosseous, or plantar) and course (transverse, longitudinal, or oblique,). Transverse ligaments connect adjacent tarsal (intertarsal) or metatarsal (intermetatarsal) bones. Longitudinal ligaments extend from the tarsal to its corresponding metatarsal bone. Oblique ligaments extend from one tarsometatarsal ray to an adjacent one.

The dorsal ligaments (see **Fig. 3**B) include a variable number of short, flat, ribbonlike horizontal, oblique, or longitudinal bands across the tarsometatarsal joint, including one from each cuneiform to the base of M2, three fine intertarsal ligaments (transverse at C1-C2 and C2-C3, and oblique from C3-Cu), and three fine ribbonlike transverse intermetatarsal ligaments (M2-M3, M3-M4, and M4-M5). No substantial M1-M2 fibers were observed.

Interosseous ligaments (see **Fig. 3**C) include three cuneometatarsal ligaments (the Lisfranc ligament, the central ligament, and the lateral longitudinal ligament), three intermetatarsal ligaments (M2-M3, M3-M4, M4-M5), and three intertarsal ligaments (C1-C2, C2-C3, and C3-Cu).

The Lisfranc ligament (first interosseous ligament, medial interosseous ligament, or interosseous C1-M2 ligament) is the largest of the ligaments supporting the Lisfranc joint. It has an oblique distal, lateral, and plantar course from the lateral wall of C1, adjacent to the C1-C2 intercuneiform ligament, to the medial base of M2 just beyond the articular surface. The plantar surface is intimately associated with the adjacent C1-C2 interosseous ligament, plantar ligaments, and the peroneus longus tendon. The central ligament (second cuneometatarsal ligament) extends from C2-C3 anteriorly to M2-M3 in most, but was variable. The lateral longitudinal ligament (third cuneometatarsal ligament) extends between C3 and M3 laterally.

The intertarsal interosseous ligaments are thick strong ligaments between C1-C2 (medial intercuneiform interosseous ligament), C2-C3 (lateral intercuneiform interosseous ligament), and C3-Cu (cuneocuboid interosseous ligament). Medial (M2-M3), central (M3-M4), and lateral (M4-M5)

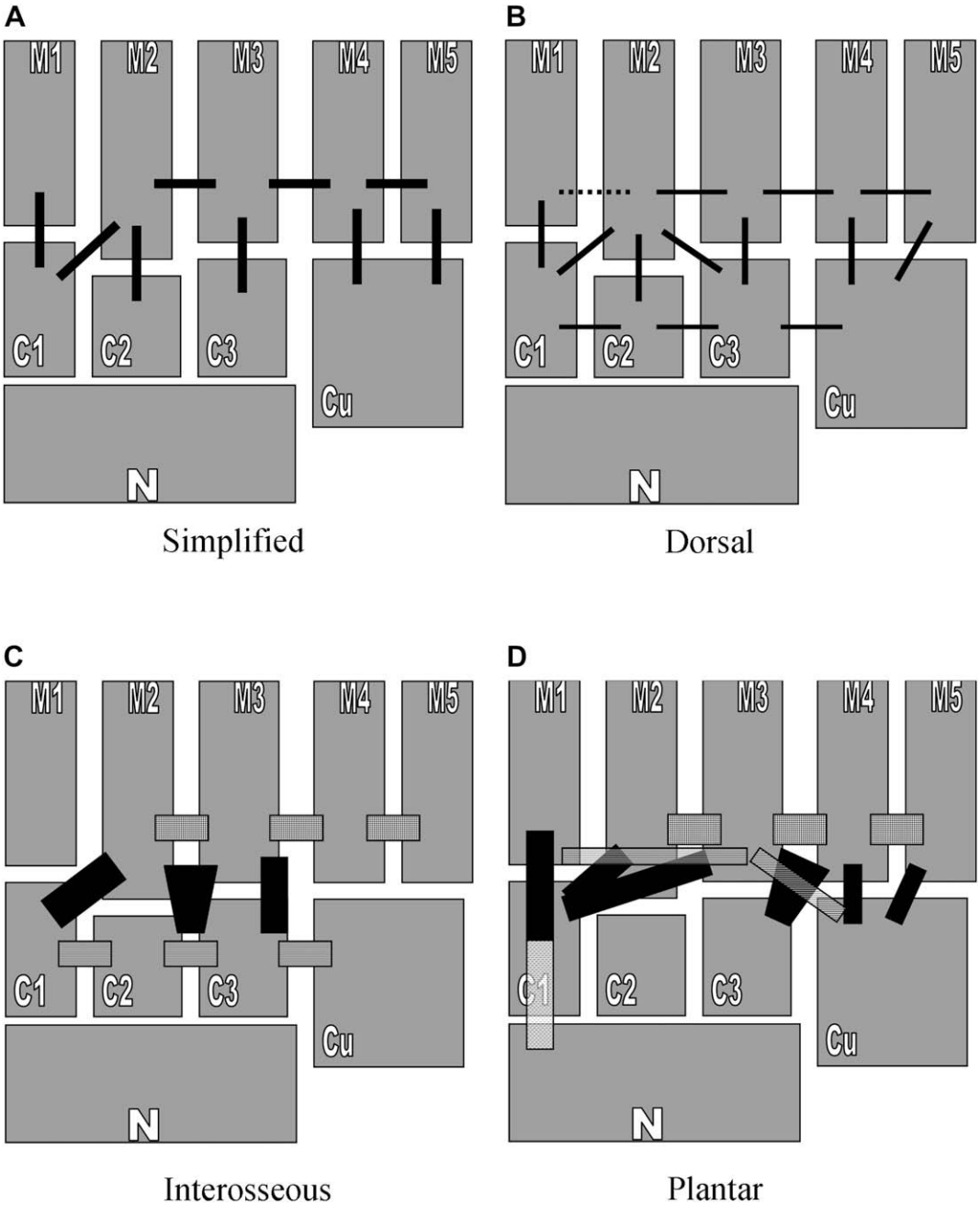

Fig. 3. Ligamentous constraints. (*A*) Simplified approach to the Lisfranc ligamentous constraints emphasizes absence of M1-M2 intermetatarsal ligament and presence of C1-M2 Lisfranc ligament. (*B*) Dorsal ligaments are thinner and weaker than the interosseous and plantar ligaments. Insignificant M1-M2 ligaments are occasionally identified (*dashed line*). (*C*) Interosseous ligaments, including the C1-M2 Lisfranc ligament, are substantial on gross inspection and mechanical evaluation. (*D*) Plantar ligaments are also substantial. The plantar C1-M2M3 ligament is an important contributor to Lisfranc stability. Refer to text for detailed description. Solid lines in B–D indicate tarsometatarsal ligaments, grid indicates intermetatarsal ligaments, stripes indicate intertarsal ligaments, and dashes indicate an inconstant relationship.

intermetatarsal interosseous ligaments tie the lesser metatarsals to each other.

Plantar ligaments (see **Fig. 3**D) were also found to be variable in size, number, and course. These were strong medially and weaker laterally. The first plantar ligament extended between C1-M1 and variably was in continuity with the more proximal ligament between the navicular and C1. The second ligament was oblique and coursed from C1 to the bases of M2 (thin and deep) and M3 (thick and superficial); this was the strongest of the plantar ligaments. No C2-M2 plantar ligaments were found. The third plantar ligament connected C3 to M3, M4, or both. The fourth and fifth ligaments connected the cuboid to the fourth and fifth, respectively, but were absent in roughly one third. Plantar intermetatarsal and intertarsal ligaments were stronger than the dorsal ligaments. The three intermetatarsal plantar ligaments course transversely and are the medial (M2-M3), central (M3-M4), and lateral (M4-M5); no ligaments extend from M1-M2. The plantar intertarsal ligaments consist of a single band from the base of M1 to M3 (without significant M2 attachment) and a band from M3-Cu.

Solan and colleagues[19] in 2001 reported results of their ex vivo biomechanical investigation of the ligaments of the second tarsometatarsal joint. They used paired cadaver feet and restricted their evaluation to the dorsal C1-M2, interosseous Lisfranc C1-M2, and plantar C1-M2M3 ligaments, and the adjacent bony structures C1, M2, and M3. Initial comparisons showed that the dorsal ligaments were weaker than the Lisfranc/plantar ligamentous complex. Subsequent evaluation revealed that the Lisfranc ligament was significantly stronger and stiffer than the plantar ligaments. These findings were consistent with earlier morphologic anatomic observations.[11,21]

In 2007, Kaar and colleagues[20] reported the results of their cadaveric study in which they sequentially sectioned the ligamentous stabilizers of the Lisfranc joint and evaluated simulated weightbearing (WB) and stress radiographs to assess stability. After initial sectioning of the Lisfranc (interosseous C1-M2) ligament, only 10% of specimens showed C1-M2 instability on simulated WB radiographs, 40% on abduction stress views, and none with adduction stress. They then sectioned either the plantar C1-M2M3 ligament or the C1C2 intercuneiform ligament. After additional sectioning of the plantar C1-M2M3 ligament, 20% showed instability based on C1-M2 widening (0% based on C2-M2) on WB and 100% displaced at both C1-M2 and C2-M2 with abduction stress. The second subgroup, after sectioning of the Lisfranc and then first intercuneiform interosseous ligament (C1-C2), showed instability at C1-M2 in 20% and C1-C2 in 20%. With adduction stress, 20% showed C1-M2 widening and 80% showed C1-C2 instability. They concluded that transverse instability (C2-M2 tarsometatarsal widening) required section of the Lisfranc and plantar ligaments and was best appreciated under abduction stress. On the other hand, longitudinal instability (C1-C2 intercuneiform widening) required sectioning of the Lisfranc and C1-C2 ligaments and was best appreciated under adduction stress. Presumably working from the assumption that the Lisfranc ligament had to be injured to develop either longitudinal or transverse instability, they did not section either the plantar or intercuneiform ligaments in isolation, nor did they evaluate the combination of plantar and intercuneiform disruption.

Additional support of the tarsometatarsal joints is provided by soft tissues of the plantar foot, including the tendons of the peroneus longus, anterior and posterior tibialis, the long plantar ligament, the plantar fascia, and intrinsic muscles.[20,22] The relative support provided by these and the extent to which their disruption contributes to Lisfranc injuries has not yet been established.

INJURY MECHANISM

Injuries to the joint can be due to direct forces applied to the tarsometatarsal joint but much more commonly result from indirect forces applied away from the joint, which act on it secondarily. The former account for some high-velocity injuries and the latter for most low-energy injuries.[23] High-velocity injury mechanism may be related to crush injury. As a result, displacement can be either dorsal or plantar depending on the direction of force and the site of application.[14] There are often numerous associated fractures within the foot and at distant sites.[3] Extensive associated soft tissue injuries are common, including vascular compromise and compartment syndrome.[22] These distracting injuries may contribute to missed or delayed diagnosis in this patient group.

Indirect forces account for most athletic injuries and typically occur as a result of forced plantar flexion or forefoot abduction, nearly always resulting in dorsal displacement of the metatarsals.[14] Other mechanisms include rolling the foot when stepping off a step or curb.[10,23]

Plantar flexion injuries can occur in several different ways. In the tiptoe position of full ankle and metatarsophalangeal plantar flexion, full body weight loads the Lisfranc joint along an elongated lever arm, resulting in failure of the joint dorsally and plantar flexion. This mechanism

occurs in dancers and is similar to what happens during a misstep off of a curb or step, with the forefoot being "rolled over" by the entire body. Alternatively, if the ankle is plantar flexed while the knee is on the ground, a force directed along the axis of the foot can cause similar plantar flexion and dorsal failure; this is the purported mechanism in the football pileup where a player lands with full body weight on another's heel while the ankle is plantar flexed and the knee is on the ground.[23,24]

Forefoot abduction injuries occur when an athlete, typically wearing cleats, plants his foot and rotates to change direction.[10] Similar mechanism occurs in sailboarders and equestrians whose forefoot is fixed by a strap or stirrup.[25]

INJURY CLASSIFICATION

There has been an evolution in the classification of Lisfranc injuries over the past century; Quenu and Kuss[26] in 1909 placed Lisfranc injuries into three categories: homolateral, isolated, and divergent. In homolateral injuries all five metatarsals are displaced in one direction. Divergent injuries occur when metatarsals are displaced in different directions in the sagittal and coronal planes. Isolated injuries do not involve all five metatarsals.

First Hardcastle and colleagues in 1982[27] and then Myerson and colleagues in 1986[14] expanded on the Qenu and Kuss classification to more comprehensively describe the spectrum of injuries at the Lisfranc joint (**Fig. 4**).

- Type A: total incongruity of the Lisfranc joint, typically either lateral or dorsoplantar
- Type B: partial incongruity
  - B1: partial medial dislocation, essentially involving the first ray in isolation, with or without displacement of the medial cuneiform
  - B2: partial lateral dislocation, involving any of the other four metatarsals
- Type C: divergent displacement
  - C1: partial
  - C2: total

Although useful for standardizing terminology, and applicable to low- and high-impact injuries, these classifications have not been found to predict outcome.[10,14]

Curtis and colleagues[10] in 1993 reported the first series limited to athletic midfoot injuries and used the American Medical Association's *Standardized Nomenclature of Athletic Injuries* to classify injuries. First- and second-degree injuries were partial tears of the tarsometatarsal ligaments without instability on examination or fluoroscopic evaluation. Third-degree sprains were defined as complete ligamentous rupture with radiographic diastasis. The Myerson classification was applied to fracture-dislocations. This classification did not predict return to sport: 3 of 19 patients were unable to return to their sport and 2 of these had been classified as low-grade sprains.

Nunley and Vertullo[28] reviewed their experience with athletic midfoot injuries in 2002 and staged them based on a combination of clinical findings, bilateral AP, oblique and lateral WB radiographs, and radionuclide bone scans. Patients who had stage I injuries were unable to continue to play, had pain at the Lisfranc complex, and were nondisplaced radiographically, but demonstrated increased uptake on bone scan. Stage II injured athletes showed M1-M2 diastasis 1 to 5 mm greater than the uninjured foot but no loss of midfoot arch height. Stage III injuries had more than 5 mm of M1-M2 diastasis and arch height loss revealed by decrease in the C1-M5 distance on lateral view compared with the uninjured foot. Displaced injuries were further classified using the Myerson classification. This staging system drove patient management and they achieved excellent outcomes in 93% with nonoperative management of Stage I and operative management of Stage II and III injuries.

IMAGING

The initial imaging evaluation of the Lisfranc joint should be by radiography. At the Cleveland Clinic the initial radiographic series for injury or trauma is performed unilaterally and consists of nonweightbearing (NWB) AP, internal oblique, and lateral views. Although these radiographs may readily demonstrate fracture or malalignment, often Lisfranc injuries are inapparent or subtle. Nunley and Vertullo[28] found that 50% of their athletes who had midfoot sprains had normal NWB radiographs. In patients who had subtle abnormalities on NWB films, or in patients who had a high clinical concern for midfoot sprain, WB radiographs are advised, with pain control as necessary.[9] A standing AP including both feet should be obtained, along with a WB lateral of the injured foot. Some authors advocate obtaining a comparison contralateral WB lateral view also (**Fig. 5**).[29]

Radiographic assessment of the Lisfranc joint requires a careful search for fracture on all views. In particular, fractures are common at the plantar medial base of M2 and plantar lateral base of C1. Myerson[14] coined the term "fleck sign" to describe these subtle cortical avulsion fractures from either

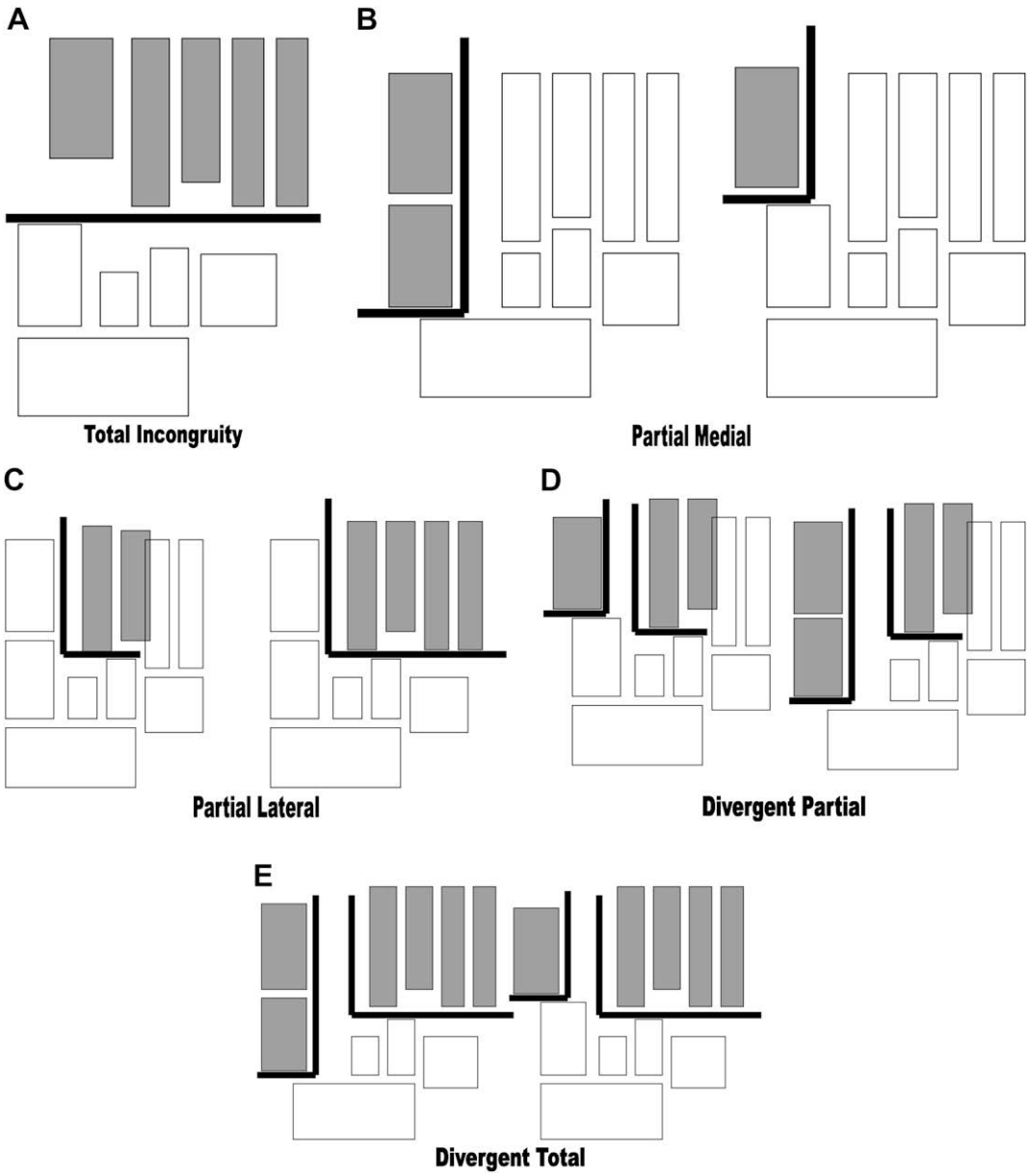

Fig. 4. Classification according to Myerson[14] is applied to both high- and low-velocity injuries. Shaded areas indicate displaced segments and black lines indicate lines of force. (*A*) A, total incongruity can result in displacement of all five metatarsal in any one direction (homolateral) but is typically dorsolateral. (*B*) B, partial incongruity. B1, Medial column disruption can occur either through C1-M1 or N-C1 joints. (*C*) B2, middle, or both middle and lateral column subluxation. (*D*) C1, divergent partial incongruity involves medial and middle columns. (*E*) C2, divergent total incongruity involves all metatarsals with medial column displaced medially and middle and lateral columns displaced laterally.

attachment of the Lisfranc ligament. These are three times more common in polytrauma patients than athletes,[10,14] and must be differentiated from the normal variant accessory ossicle (os intermetatarseum) that occurs slightly more distally in the first intermetatarsal web site, and which is typically smoothly corticated (**Fig. 6**).

Careful attention should also be directed to tarsometatarsal alignment, because even the subtlest of malalignments may portend a significant injury. The asymmetry of the dorsoplantar Roman arch of the cuneiforms, which is elongated laterally, leads to visualization of different portions of the joint on the anteroposterior versus

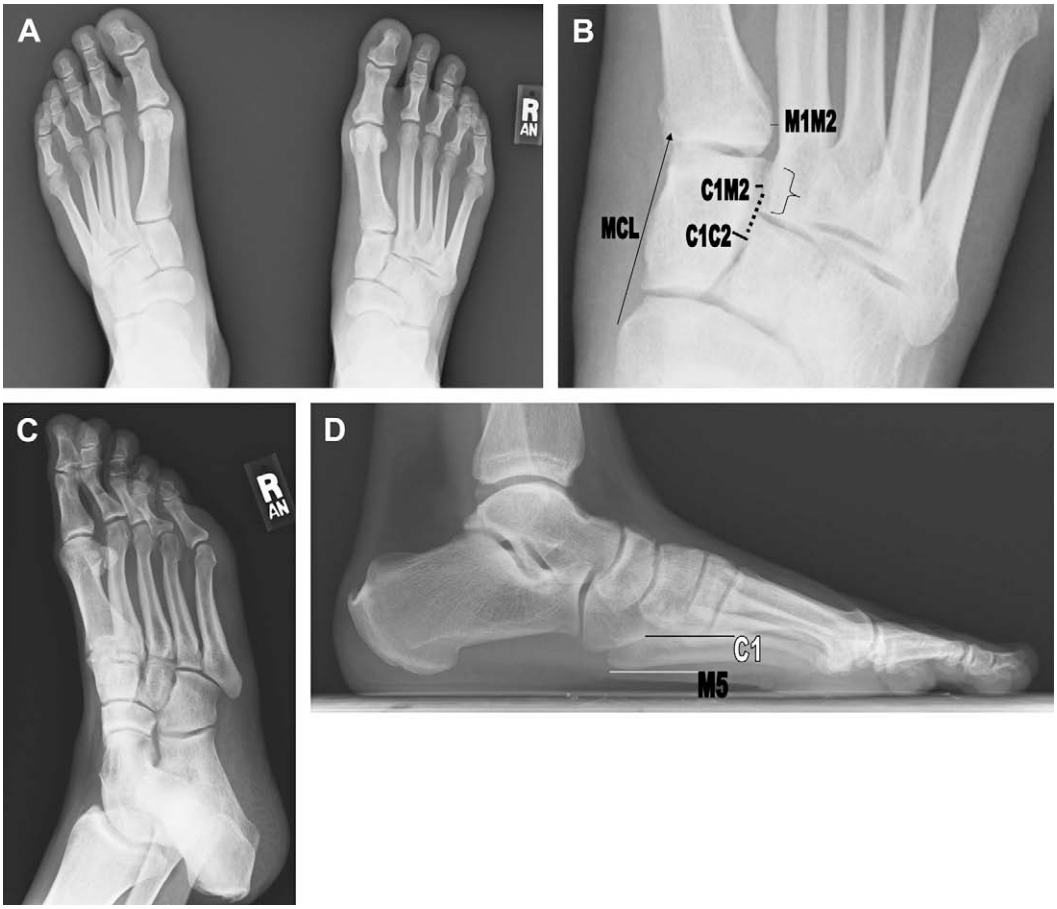

Fig. 5. Normal three-view foot series. (*A*) WB AP of both feet. (*B*) Magnification of A annotated with relationships to evaluate for suspected Lisfranc injury. Dashed line indicates second tarsometatarsal alignment. Bracket indicates depth of medial recess of the M2. (*C*) Oblique view. Note near-perfect alignment of medial and lateral margins of C2-M2, lateral margin of C3-M3, and medial margin of Cu-M4. (*D*) WB lateral. Note dorsal position of the plantar aspect of C1 with respect to plantar aspect of M5, perfect dorsal alignment of C1-M1 and C2-M2, and near-neutral talometatarsal angle.

oblique projections. On the AP view, the lateral margin of the first tarsometatarsal and medial margins of the second[30] and third[31] tarsometatarsals should each align nearly perfectly. On the oblique view, the lateral margins of C2-M2 and C3-M3 should align. The alignment of the fourth TMT is more variable but should be within 2 to 3 mm.[30–32]

On the WB lateral radiograph, images should be scrutinized for dorsoplantar subluxation or angulation and loss of the medial plantar arch:

- There should be no step-off at the dorsal margins of the tarsometatarsal joints[9]
- The talometatarsal angle is normally less than 10 degrees[14]
- The plantar surface of the medial cuneiform should project dorsal to the plantar aspect of M5[29]

Various authors have used differing thresholds for measurements related to these alignments and relationships, whereas others emphasize additional measurements:

- M1-M2 asymmetry with widening >1 mm on AP of the injured foot[28]
- Any disruption of the medial C2-M2 line on the AP[28]
- C1-C2 asymmetry with widening >1 mm on AP of the injured foot[28]
- C1-M2 asymmetry with widening >2 mm on WB AP[33]
- Failure of a line drawn on an AP along the medial margins of the navicular and C1 (medial column line) to intersect M1[34]
- C1-M5 asymmetry with narrowing >1.5 mm, or reversal, on the affected side on the WB lateral view[29] (**Fig. 7**)

Fig. 6. Acute left foot racquetball injury, Myerson B2. Remote right Lisfranc injury. (*A*) WB AP shows lateral subluxation of the left C2M2 joint with diastasis of M1M2, C1M2, and C1C2. Note shallow depth of recession of each M2, perhaps predisposing him to injury. (*B*) Magnified and coned image show smoothly corticated and distal os intermetatarseum (*white arrow*) and proximal fleck fracture (*circled*). (*C*) Oblique view shows C2-M2 and C3-M3 malalignment and additional fracture lateral to the M2 base. (*D*) Oblique axial CT image shows both the os intermetatarseum (*white arrow*) and fleck fracture (*circled*). (*E*) Oblique axial CT image shows numerous radiographically occult fracture fragments from the dorsum of C3. (*F*) Long axis CT reconstruction shows subtle malalignment of the C2-M2 and C3-M3 joints. (*G*) Despite operative reduction and fixation, WB AP 10 months later shows early C2-M2 arthrosis.

Talometatarsal angle >15 degrees on the lateral view[14]

Radiographic assessment is limited by difficulties with accuracy and reproducibility.[33–36] In general, however, lateral step-off at the second tarsometatarsal joint is accepted as the most common and reliably detected abnormality in Lisfranc injuries,[17] with diastasis of 2 mm or more indicating instability.[14,20,28]

In addition, normal WB views have been reported in patients who have midfoot sprains and Lisfranc injuries even on retrospective review.[24,28,33,36] False-negative WB views may be related to soft tissue swelling or pain limiting the degree of WB.[36] Stress radiographic views, radionuclide bone scan, CT, and MR imaging may each have a role in evaluating these injuries. At the present time no consensus imaging algorithm exists.

Fig. 6. (*continued*).

Stress views are advocated for their ability to directly demonstrate instability when initial radiographs are normal or show minimal diastasis.[6,10,20,34,37] Anesthesia may be necessary to achieve adequate pain control.[10] Pronation-abduction stress is most commonly advocated, although Kaar and colleagues emphasized the importance of adduction stress views in identifying longitudinal instability patterns of the first ray.[20]

Radionuclide bone scans are advocated for their ability to identify a midfoot sprain in the absence of radiographic findings,[28] particularly in patients presenting long after the initial injury.[6,8]

Fig. 7. WB lateral shows reversal of the normal relationship of C1 and M5, with C1 plantar to M5. Note severe tarsometatarsal osteoarthritis in this patient who had chronic Lisfranc injury.

Multidetector CT exquisitely depicts osseous anatomy and articular alignment in essentially any plane (see **Fig. 6**D–F).[36] Direct visualization of ligaments is limited, however, and WB or stress imaging is not practically feasible.[17] Tarsal fractures[36,38] and tarsometatarsal malalignment[38,39] are more readily identified on CT than radiographs. Tarsal fractures, in addition to the cuneiforms, can involve any of the bones of the feet but most frequently the cuboid.[36] The principle role of CT in the assessment of tarsometatarsal injuries is improved detection and delineation of fractures and their degree of comminution, intra-articular extension, displacement,[40] and any interposed soft tissues, typically tendons, that could preclude reduction.[1] As a result, CT is particularly recommended in patients who have high-velocity midfoot injuries or when fractures other than simple fleck signs are identified on initial radiographs.[7,36,38,41]

In contradistinction, MR imaging excels at depiction of soft tissues (see **Fig. 7; Figs. 8** and **9**); in the author's experience and literature review there are no reports of falsely positive or negative MR imaging with respect to Lisfranc ligament injuries. Preidler and colleagues[36,42,43] published a series of three papers investigating MR imaging of the normal and injured Lisfranc joint from 1996 to 1999. In a cadaver study, they initially established that MR imaging reliably depicted the anatomy of the tarsometatarsal joint and promoted oblique axial images (proscribed along the long axis of the foot parallel to the dorsum) to evaluate bony alignment and the interosseous Lisfranc ligament. Tarsometatarsal ligaments were best visualized in the sagittal plane. Intermetatarsal ligaments were seen best in the coronal (short axis of foot) images, and were thicker plantarly. MR arthrography performed after injection of each tarsometatarsal compartment did not improve visualization of the ligamentous anatomy.[42]

Shortly thereafter, Preidler and colleagues[43] reported their experience with MR imaging of Lisfranc injuries in 11 patients. MR imaging identified malalignment in all 11 patients at the second tarsometatarsal joint, confirming the radiographic findings in all 5 patients for whom radiographs were available. The interosseous Lisfranc ligament was disrupted in 8 patients and the remaining 3 had fractures of either the M2 base or lateral wall of C1. Additionally, intermetatarsal ligament injuries, other metatarsal fractures, and tarsal fractures were identified. In the 9 patients who were treated surgically, all MR imaging findings were confirmed.

Subsequently, Preidler and colleagues[36] reported results from a prospective study of 49 patients who had acute midfoot hyperflexion injuries attributable to low- and high-impact mechanisms and proved the impact of additional imaging beyond radiographs on patient management. Each patient underwent routine and WB radiographs the day of injury, CT within 2 days, and MR imaging within 5 days. Eight patients had tarsometatarsal malalignment on routine and WB views; an additional 8 showed malalignment on CT and MR imaging. CT and MR imaging also each demonstrated more fractures than were seen on radiographs: CT revealed more than 50% more metatarsal and twice as many tarsal fractures; MR imaging showed about 25% more metatarsal fractures and just under twice as many tarsal fractures, and numerous additional bone bruises. Some of these bone bruises correlated with nondisplaced cortical fractures seen on CT but misdiagnosed as bone bruises on MR imaging. Imaging findings were confirmed in the 11 patients who went to surgery. The authors concluded that management changed in 8 patients because of findings on CT scan and that MR imaging did not further change treatment in these or change management in any other patient. They did not specifically address whether MR imaging in the absence of a prior CT would have changed management compared with radiographs alone. Their results strongly suggest that it would have had a similar impact as CT, however, because all malalignments were identified on both modalities, MR demonstrated more bony injuries (although some nondisplaced fractures were misdiagnosed as bone bruises), and MR afforded direct visualization of Lisfranc ligament disruption.

Potter and colleagues[33] reported their experience evaluating the Lisfranc ligament in 23 patients who suffered midfoot injury and had radiographs and MR imaging. Most were athletes who had suffered low-impact injuries. The study was not designed to evaluate the impact of particular radiographic or MR imaging findings on patient management or outcome. A cadaver study of anatomic–MR imaging correlation was also performed. They described the Lisfranc ligament as having two bands, dorsal and plantar.

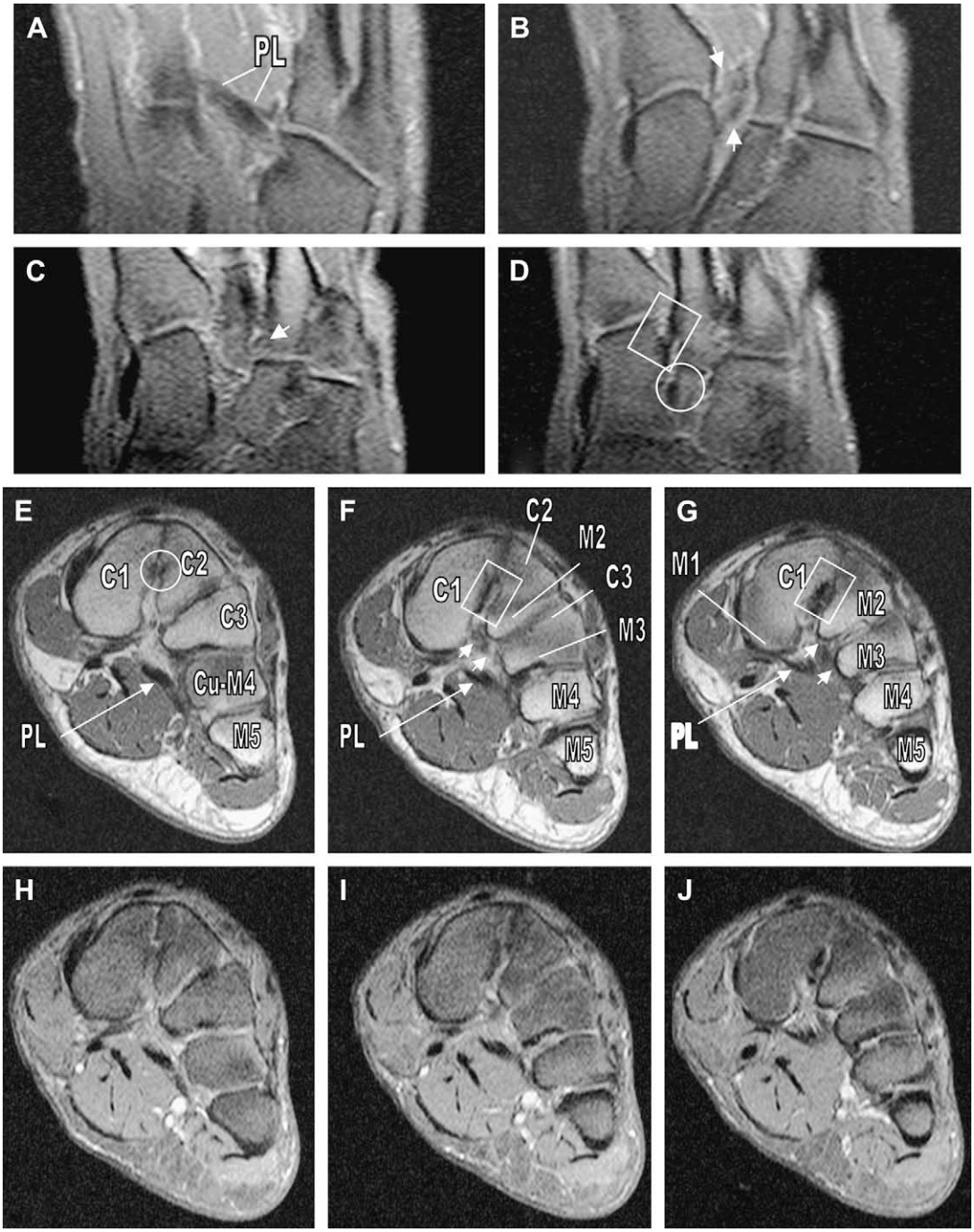

Fig. 8. Normal MR imaging of the Lisfranc Joint. (*A–D*) Consecutive plantar to dorsal fluid-sensitive oblique long axis images (fat-suppressed turbo spin echo PD TR4000/TE13). (*A*) The peroneus longus (PL) is immediately deep and orthogonal to the plantar C1-M2M3 ligament (*arrows*) in B and C. The interosseous C1-M2 Lisfranc ligament (*rectangle*) and C1-C2 interosseous ligament (*circle*) are seen in D. (*E–G*) T1 (TR687/TE15), and (*H–J*) fat-suppressed TSE T2 (TR5200/TE14) short axis images from proximal to distal. (*E*) The C1-C2 interosseous ligament (*circle*) is seen at the midportion of the cuneiforms which are closely apposed without fluid or edema. (*B*) Immediately distal is the C1 attachment of the Lisfranc C1M2 interosseous ligament (*rectangles*), which courses obliquely to attach to M2 (*G*). The plantar C1-M2M3 ligament is seen to have a slightly more longitudinal course from the base of C1 to the tip of M1 and the medial base of M3 (*F, G, short arrows*). Note the underlying peroneus longus tendon as it courses from proximal lateral to distal medial to insert on the base of M1. Fluid-sensitive images H–J show no abnormal signal within the ligaments, PL, and adjacent osseous structures.

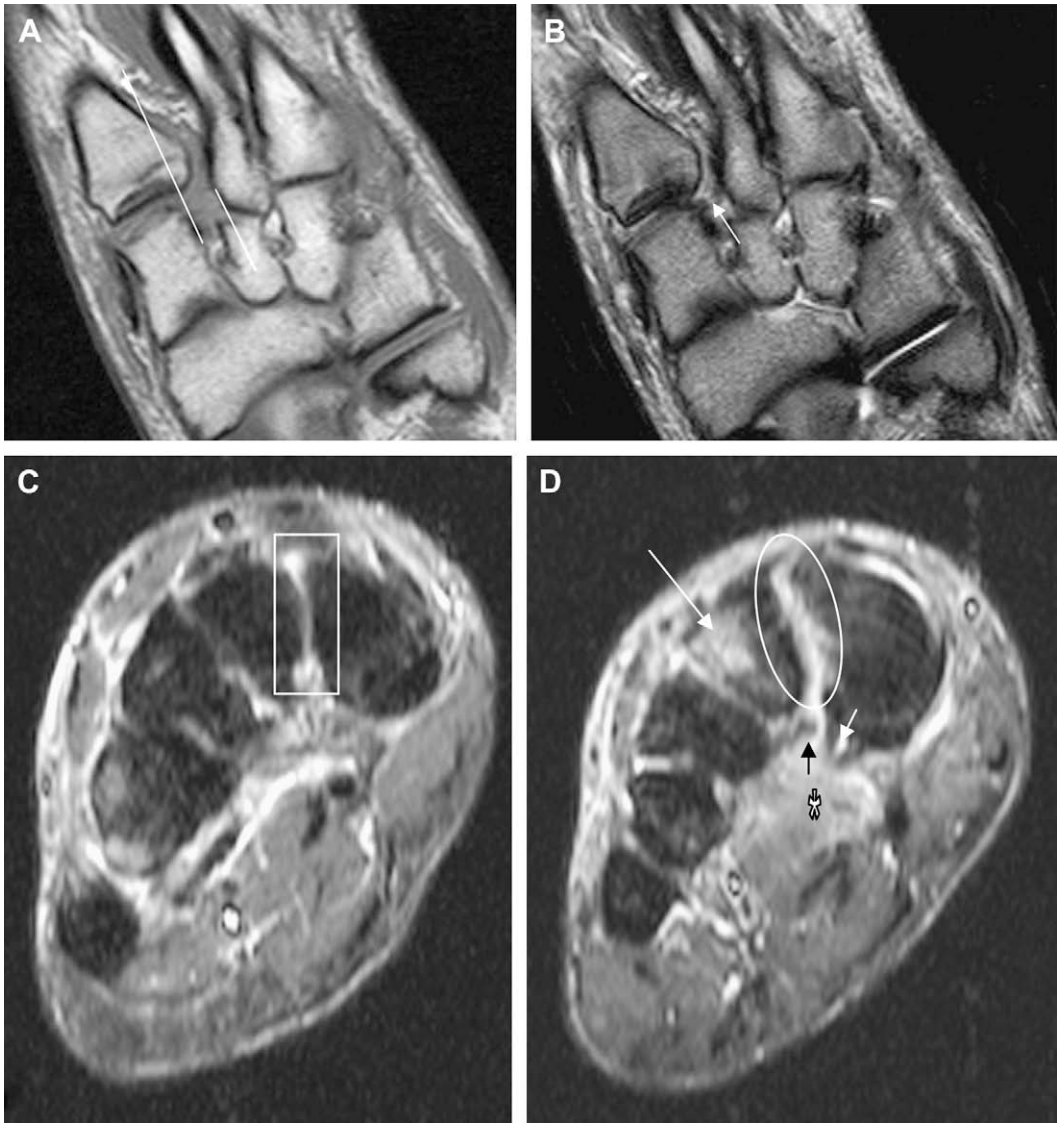

Fig. 9. Unstable Lisfranc injury, MR imaging. A 16-year-old male football player suffered a plantar flexion injury when a player landed on his heel after he had been tackled. (*A*) T1 (TR600/TE14) oblique long axis shows subtle C1-M1 and C2-M2 lateral subluxations (*lines*). (*B*) TSE T2 (TR3458/TE96) in the same plane shows complete tear of the interosseous Lisfranc ligament (*arrow*) with adjacent edema. (*C*, *D*) Inversion recovery (TR7000/TE22/TI150) short axis images. There is fluid at the first intercuneiform space and nonvisualization of the C1-C2 ligament (*rectangle*) (*C*). At the level of C1-M2 (*D*), there is abnormal increased signal in the interspace, and nonvisualization of the Lisfranc ligament (*oval*), disruption of the plantar C1-M2M3 ligament (*short black arrow*), injury to the plantar musculature (*) and peroneus longus at its insertion (*short white arrow*), and M2 base bone bruise (*long white arrow*).

The dorsal corresponded to the interosseous Lisfranc ligament, whereas the plantar corresponded by description and the limited images published with the C1-M2M3 ligament described by DePalma[11] and evaluated by Kaar and colleagues.[20] Disruption of either band was considered a partial tear (18 of 23) and disruption of both, a complete tear (3 of 23) of the Lisfranc ligament. All patients who had radiographic diastasis at C1-M2 or C2-M2 of 2 mm or more when compared with the uninjured side had partial or complete rupture of the Lisfranc ligament. All patients who had rupture of both bands had at least 2 mm diastasis at C1-M2. Radiographic abnormalities were not consistently seen in patients who subsequently had a partial tear

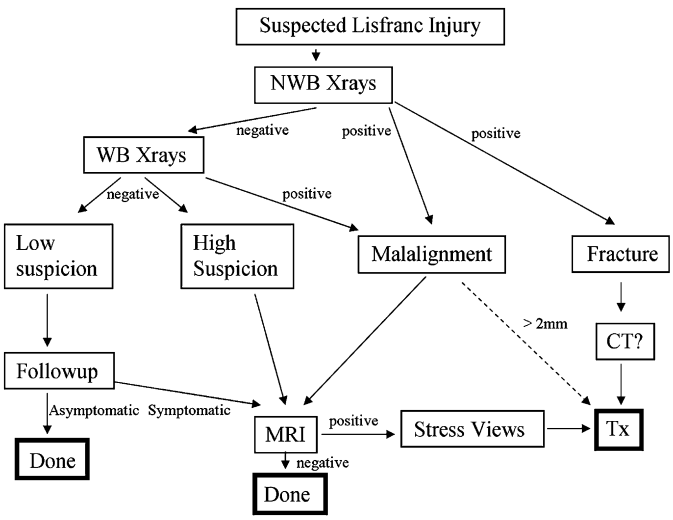

Fig. 10. Proposed imaging decision tree.

identified on MR imaging, however. Because none of this latter subset had surgery and no follow-up information was provided, the significance of identification of these partial tears involving either the interosseous or plantar ligament is uncertain. In the 7 patients who underwent surgery for partial or complete tears, the MR imaging findings were confirmed. Interestingly, additional tears were described of the intercuneiform and intermetatarsal ligaments on MR imaging in the absence of radiographic widening. Although the impact of these findings on patient management was beyond the scope of the study, it is noteworthy that all 4 patients who had C1C2 intercuneiform ligament tears also had full or essentially full-thickness tears of the Lisfranc ligament, radiographic asymmetric C1C2 diastasis of at least 1 mm, and went to surgery. They concluded that MR imaging is not indicated if radiographs are clearly abnormal, but can reveal the extent of ligament injury when radiographs are equivocal.

A recent case report by Hatem and colleagues[24] supported this assertion. Lisfranc ligament disruption was diagnosed with MR imaging despite normal WB radiographs; instability was confirmed by intraoperative stress view before surgical fixation.

Delfaut and colleagues[35] sounded a note of caution with respect to MR imaging interpretation in their study of tarsometatarsal joint alignment in cadavers and asymptomatic volunteers. All had intact Lisfranc ligaments, but step-offs were commonly identified at the first three tarsometatarsal joints, lateral more so than medial. These were typically identified on only a single or limited number of slices, and were believed to be related to the complexity of the anatomy in this region, joint laxity, and partial volume averaging. They cautioned that care should be taken to not overstate the significance of malalignment identified on MR imaging in the absence of ligamentous or osseous signal abnormality.

MR imaging protocols should be optimized to the scanner being used, institutional demands, and history available at the time of the examination. In general, I find useful sequences include fluid-sensitive (fat-suppressed turbo spin echo proton density/T2 or STIR) short axis (perpendicular to the tarsometatarsal joints), fluid-sensitive oblique long axis oriented parallel to the dorsum of the foot, fluid-sensitive and T1 sagittal. I have at times found a T2* weighted three-dimensional gradient echo sequence helpful because of the ability to reconstruct thin slices in multiple planes and perhaps improved visualization of cortical avulsion fragments by their susceptibility artifacts. Sagittal sequences are useful for cross-referencing exact slice positions for the other planes and assessing the dorsal tarsometatarsal ligaments. Oblique long axis images optimally visualize the interosseous Lisfranc and plantar tarsometatarsal ligaments. Short axis images also show these structures, typically over multiple slices because of the oblique courses of the ligaments, and the C1C2 intercuneiform interosseous ligament and supporting plantar structures, such as the peroneus longus and intrinsic musculature.

SUMMARY

Although there is no consensus diagnostic imaging approach in suspected Lisfranc injuries,

several important points can be garnered and are reflected in the proposed imaging flow chart (**Fig. 10**).

First, anatomic considerations, both constant and variable, contribute to tarsometatarsal injuries. The effective absence of an intermetatarsal ligament between the first two metatarsal bases, and unique osseous and capsuloligamentous anatomy of the first and second tarsometatarsal joints, accounts for the injuries sustained. Less recession of the second metatarsal base relative to the medial cuneiform predisposes to Lisfranc injury. Weaker dorsal ligaments fail first, but development of instability and its pattern seems to depend on disruption of the interosseous Lisfranc ligament, plantar tarsometatarsal ligaments, supporting plantar forefoot structures, and intercuneiform ligaments.

Second, radiographs should be carefully scrutinized for subtle malalignment or asymmetries. Asymmetric diastasis of more than 2 mm at the involved joints and spaces predicts instability and is usually an indication for prompt surgical reduction and fixation.

Third, initial normal radiographs, routine or WB, do not exclude significant Lisfranc injury and further assessment is advised when there is high clinical concern for injury or symptoms persist.

Fourth, CT's excellence in depicting malalignment and fractures makes it a useful advanced imaging technique in high-energy injuries with fractures.

Finally, the excellence of MR imaging in depicting soft tissue anatomy affords direct visualization of the Lisfranc ligament and additional capsuloligamentous structures, rendering it useful in evaluating suspected low-impact Lisfranc injuries, particularly in the setting of equivocal radiographic studies.

REFERENCES

1. Philbin T, Rosenberg G, Sferra JJ. Complications of missed or untreated Lisfranc injuries. Foot Ankle Clin N Am 2003;8:61–71.
2. Meyer SA, Callaghan JJ, Albright JP, et al. Midfoot sprains in collegiate football players. Am J Sports Med 1994;22:392–401.
3. Vuori JP, Aro HT. Lisfranc joint injuries: trauma mechanisms and associated injuries. J Trauma 1993; 35:40–5.
4. Calder JDF, Whitehouse SL, Saxby TS. Results of isolated Lisfranc injuries and the effect of compensation claims. J Bone Joint Surg Br 2004;86:527–30.
5. Sherief TI, Mucci B, Greiss M. Lisfranc injury: how frequently does it get missed? And how can we improve? Injury 2007;38:856–60.
6. Aronow MS. Treatment of missed Lisfranc injury. Foot Ankle Clin N Am 2006;11:127–42.
7. Hunt SA, Ropiak C, Tejwani NC. Lisfranc joint injuries: diagnosis and treatment. Am J Orthop 2006;35:376–85.
8. Latterman C, Goldstein J, Wukich DK, et al. Practical management of Lisfranc injuries in athletes. Clin J Sports Med 2007;17:311–5.
9. Gupta RT, Wadhwa RP, Learch TJ, et al. Lisfranc injury: imaging findings for this important but often-missed diagnosis. Curr Probl Diagn Radiol 2008; 37:115–26.
10. Curtis MJ, Myerson M, Szura B. Tarsometatarsal injuries in the athlete. Am J Spts Med 1993;21: 497–502.
11. dePalma L, Santucci A, Sabetta SP, et al. Anatomy of the Lisfranc joint complex. Foot & Ankle Int 1997;18:356–64.
12. Komenda GA, Myerson MS, Biddinger KR. Results of arthrodesis of the tarsometatarsal joints after traumatic injury. J Bone Joint Surg Am 1996;78: 1665–76.
13. Arntz CT, Hansen ST. Dislocations and fracture dislocations of the tarsometatarsal joints. Orthop Clin N Am 1987;18:105–14.
14. Myerson MS, Fisher RT, Burgess AR, et al. Fracture dislocations of the tarsometatarsal joints: end results correlated with pathology and treatment. Foot & Ankle 1986;6:225–42.
15. Bassett FH III. Dislocations of the tarsometatarsal joints. South Med J 1964;57:1294–302.
16. Peicha G, Labovitz, Seibert FJ, et al. The anatomy of the joint as a risk factor for Lisfranc dislocation and fracture-dislocation. J Bone Joint Surg Br 2002;84: 981–5.
17. Crim JS. MR imaging evaluation of subtle Lisfranc injuries: the midfoot sprain. Magn Reson Imaging Clin N Am 2008;16:19–27.
18. Wiley JJ. The mechanism of tarso-metatarsal joint injuries. J Bone Joint Surg Br 1971;53:474–82.
19. Solan MS, Moorman CT, Miyamoto RG, et al. Ligamentous restraints of the second tarsometatarsal joint: biomechanical evaluation. Foot & Ankle Int 2001;22:637–41.
20. Kaar S, Femino J, Morag Y. Lisfranc joint displacement following sequential ligament sectioning. J Bone Joint Surg Am 2007;89:2225–32.
21. Sarrafian SK. Syndesmology. In: Anatomy of the foot and ankle. Philadelphia: JB Lippincott; 1993. p. 159–217.
22. Myerson MS. The diagnosis and treatment of injury to the tarsometatarsal joint complex. J Bone Joint Surg Br 1999;81:756–63.
23. Mantas JP, Burks RT. Lisfranc injuries in the athlete. Clin Spts Med 1994;13:719–30.
24. Hatem SF, Davis A, Sundaram M. Midfoot sprain: Lisfranc ligament disruption. Orthopedics 2005;28: 75–7.

25. Mullen JE, O'Malley MJ. Sprains-residual instability of subtalar, Lisfranc joints, and turf toe. Clin Sports Med 2004;23:97–121.
26. Quenu E, Kuss G. [Etude sur les luxations du metatarse (luxations metatarsotarsiennes) du diastasis entre le 1er et le 2e metatarsien]. Rev Chir 1909; 39:281–336, 720–91, 1093–134 [in French].
27. Hardcastle PH, Reschauer R, Kutscha-Lissberg E, et al. Injuries to the tarsometatarsal joint: incidence, classification and treatment. J Bone Joint Surg Br. 1982;64:349–56.
28. Nunley JA, Vertullo CJ. Classification, investigation and management of midfoot sprains. Am J Spts Med 2002;30:871–8.
29. Faciszewski T, Burks RT, Manaster BJ, et al. Subtle injuries of the Lisfranc joint. J Bone Joint Surg Am 1990;72:1519–22.
30. Foster SC, Foster RR. Lisfranc's tarsometatarsal fracture-dislocation. Radiology 1976;120:79–83.
31. Norfray JF, Geline RA, Steinberg RI, et al. Subtleties of Lisfranc fracture-dislocations. AJR 1981;137: 1151–6.
32. Goiney RC, Connell DG, Nichols DM. CT evaluation of tarsometatarsal fracture-dislocation injuries. AJR 1985;144:985–90.
33. Potter HG, DeLand JT, Gusmer PB, et al. Magnetic resonance imaging of the Lisfranc ligament of the foot. Foot Ankle Int 1998;19:438–46.
34. Coss HS, Manos RE, Buoncristiani A, et al. Abduction stress and AP weightbearing radiography of purely ligamentous injury in the tarsometatarsal joint. Foot Ankle Int 1998;19:537–41.
35. Delfaut EM, Rosenberg ZS, Demondion X. Malalignment at the Lisfranc joint: MR features in asymptomatic patients and cadaveric specimens. Skeletal Radiol 2002;31:499–504.
36. Preidler KW, Peicha G, Lajtai G, et al. Conventional radiography, CT, and MR imaging in patients with hyperflexion injuries of the foot: diagnostic accuracy in the detection of bony and ligamentous changes. AJR Am J Roentgenol 1999;173:1673–7.
37. Arntz CT, Veith RG, Hansen ST. Fractures and fracture-dislocations of the tarsometatarsal joint. J Bone Joint Surg Am 1988;70:173–81.
38. Haapamaki V, Kiuru M, Koskinen S. Lisfranc fracture-dislocation in patients with multiple trauma: diagnosis with multidetector computed tomography. Foot Ankle Int 2004;25:614–9.
39. Lu J, Ebraheim NA, Skie M, et al. Radiographic and computed tomographic evaluation of Lisfranc dislocations: a cadaver study. Foot Ankle Int 1997;18:351–5.
40. Thordarsen DB. Fractures of the midfoot and forefoot. In: Myerson MS, editor. Foot and ankle disorders, vol. 2. Toronto: WB Saunders; 1999. p. 1265–96.
41. Engalnoff G, Anglin D, Hutson HR. Lisfranc fracture-dislocation: a frequently missed diagnosis in the emergency department. Ann Emerg Med 1995;26: 229–33.
42. Preidler KW, Wang Y, Brossman J, et al. Tarsometatarsal joint: anatomic details on MR images. Radiology 1996;199:733–6.
43. Preidler KW, Brossman J, Daenen B, et al. MR imaging of the tarsometatarsal joint: analysis of injuries in 11 patients. AJR 1996;267:1217–22.